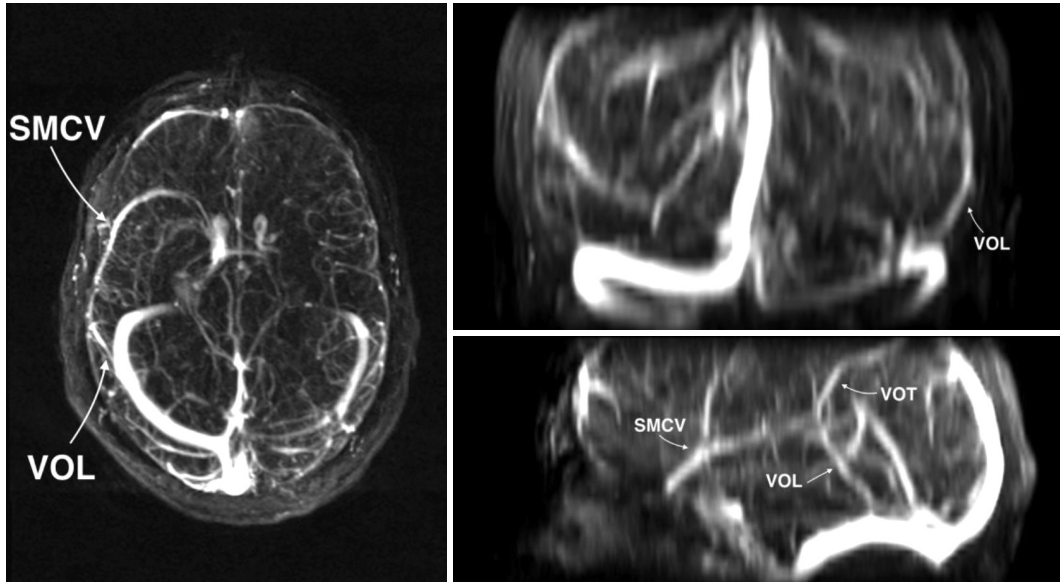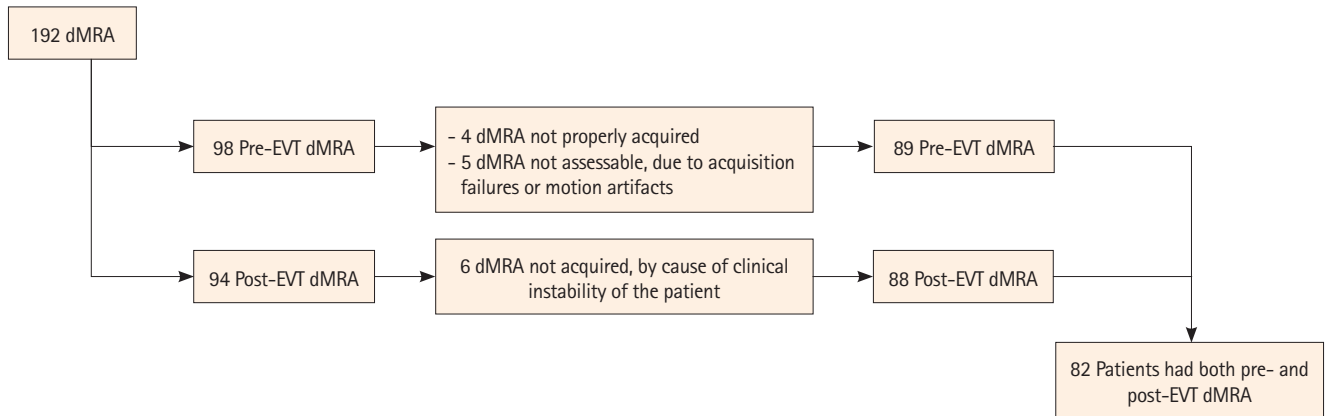


Supplementary Figure 1. Cortical veins on maximum intensity projection in the three planes of space. SMCV, superficial middle cerebral vein; VOT, vein of Trolard; VOL, vein of Labbé.



Supplementary Figure 2. Flowchart of the dMRA selection. dMRA, dynamic magnetic resonance angiography; EVT, endovascular treatment.