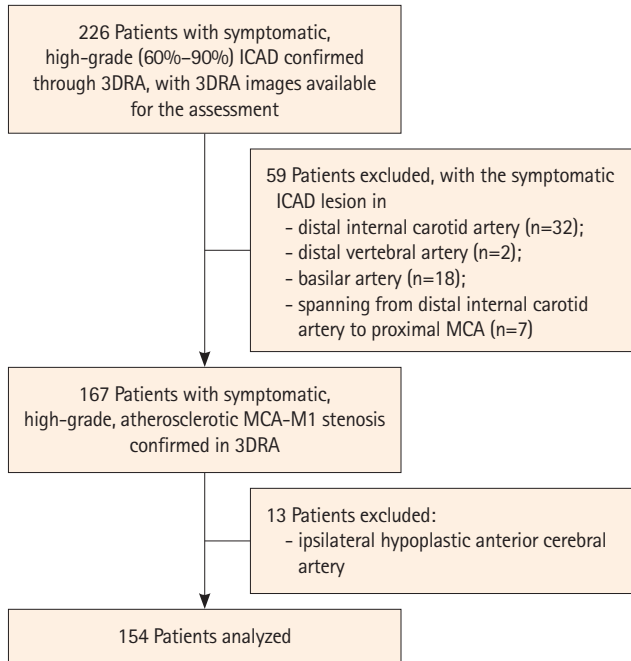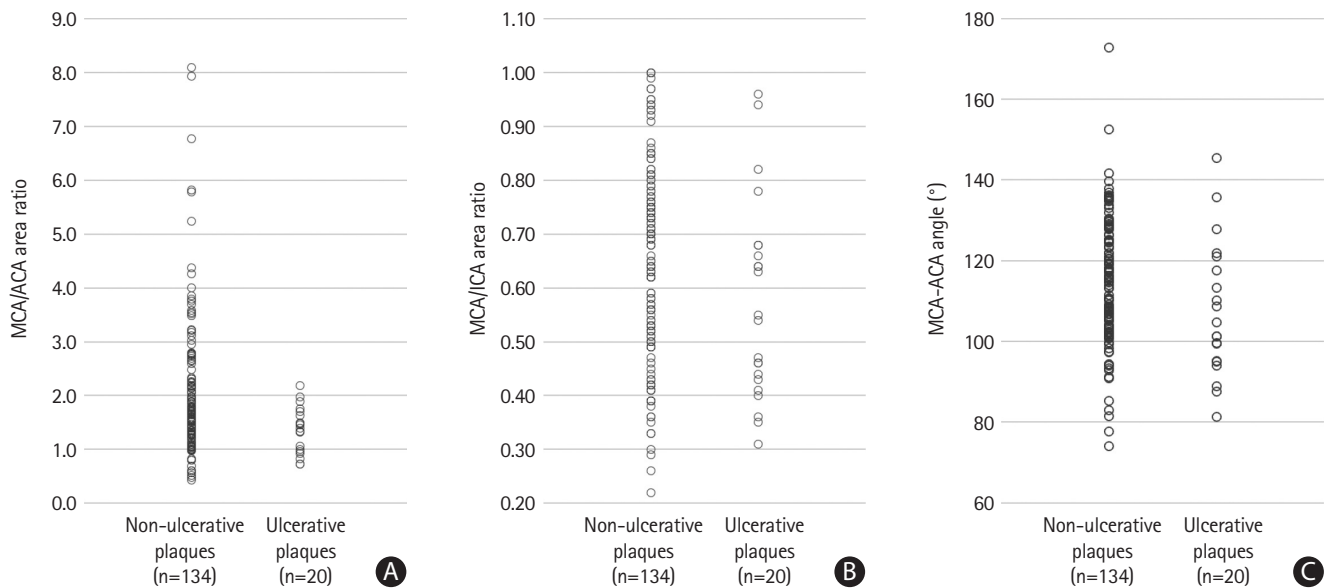


Supplementary Figure 1. Flowchart for patient screening. ICAD, intracranial atherosclerotic disease; 3DRA, three-dimensional rotational angiography; MCA, middle cerebral artery.



Supplementary Figure 2. Scatterplots showing MCA/ACA and MCA/ICA area ratios and MCA-ACA angle in patients with non-ulcerative and ulcerative MCA-M1 plaques. Smaller MCA/ACA (medians 1.36 vs. 1.71; $P=0.007$) and MCA/ICA area ratios (0.51 vs. 0.65; $P=0.029$) and MCA-ACA angle (103.1° vs. 113.2° ; $P=0.046$) were observed in patients with ulcerative MCA-M1 plaques than in those with non-ulcerative MCA-M1 plaques. MCA, middle cerebral artery; ACA, anterior cerebral artery; ICA, internal carotid artery.