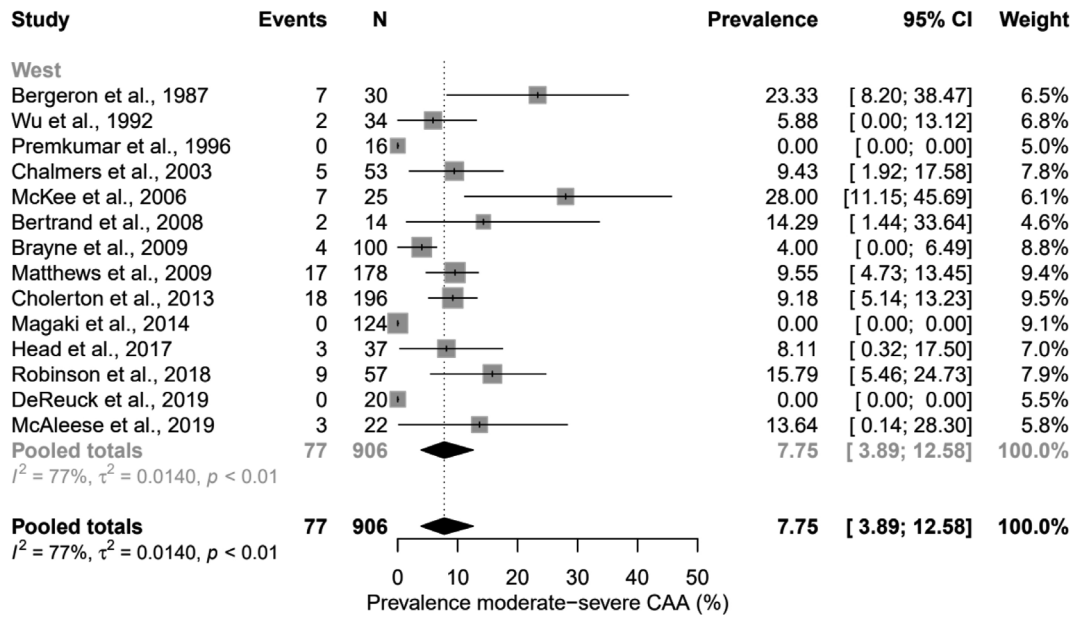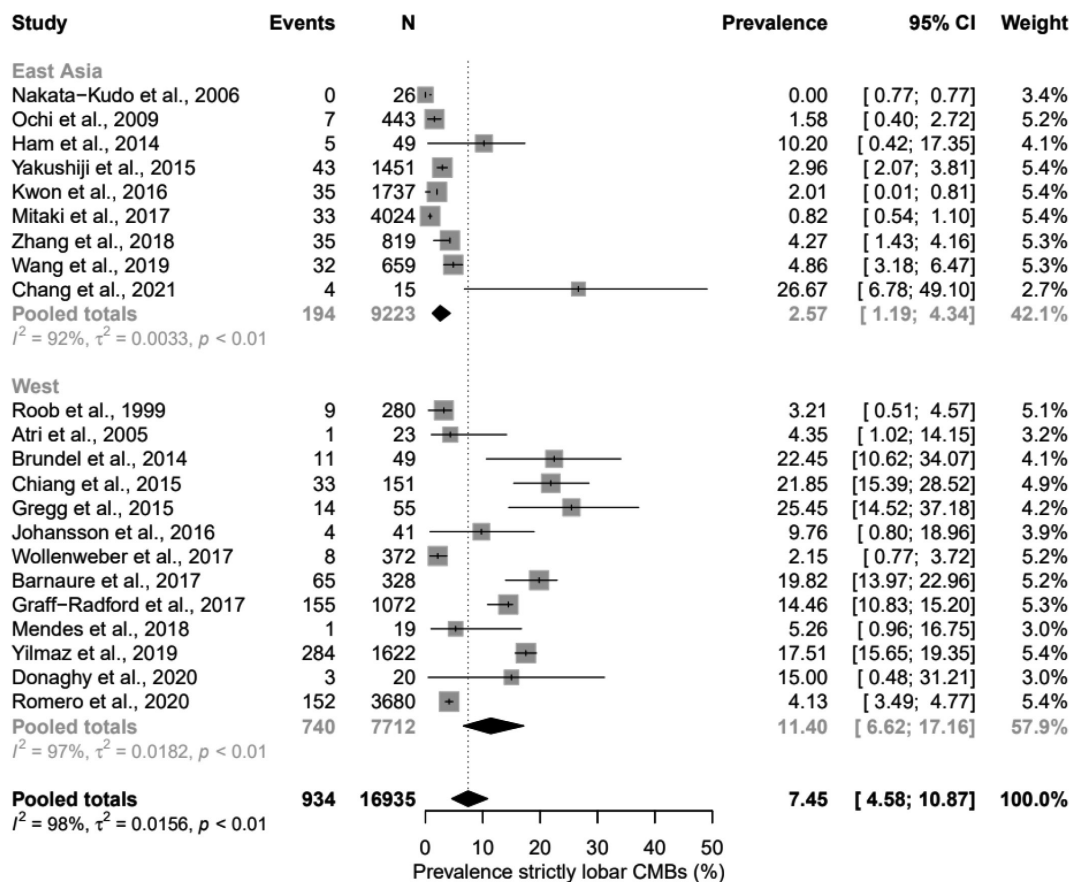


Supplementary Figure 3. Forest plots showing the prevalence of moderate-to-severe CAA pathology in Western cognitively normal elderly. No studies were included that reported on the prevalence of moderate-to-severe CAA pathology in East Asian cognitively normal elderly. CAA, cerebral amyloid angiopathy; CI, confidence interval.



Supplementary Figure 4. Forest plots showing the prevalence of strictly lobar CMBs in East-Asian and Western cognitively normal elderly. CMBs, cerebral microbleeds; CI, confidence interval.