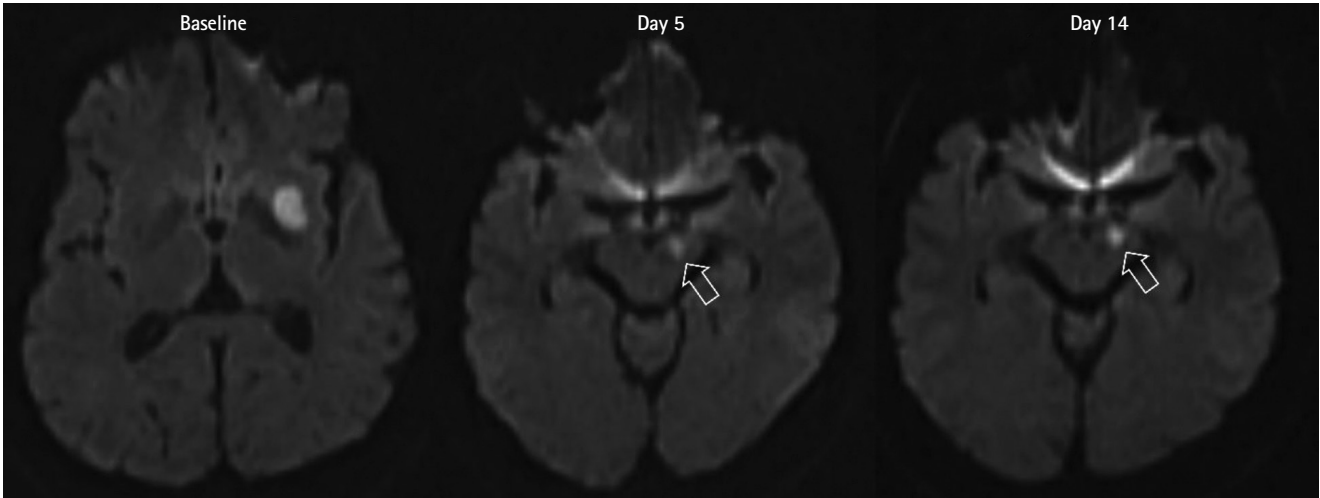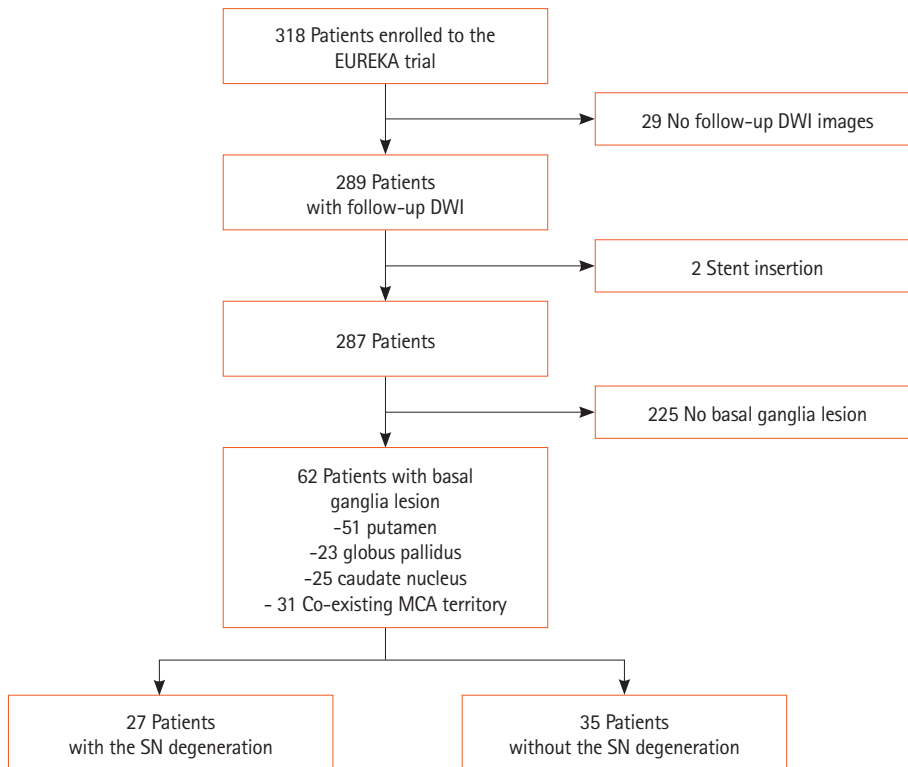


Supplementary Figure 1. Representative diffusion-weighted images showing the degeneration of the substantia nigra in the midbrain (arrows).



Supplementary Figure 2. Patient flow diagram. EUREKA, Effects of Very Early Use of Rosuvastatin in Preventing Recurrence of Ischemic Stroke; DWI, diffusion-weighted imaging; MCA, middle cerebral artery; SN, substantia nigra.